

THE EFFECT OF SURGICAL ARTIFACT ON CANNINE IN-VIVO INTERVERTEBRAL MOTION.

Michael J. Schendel, Ph. D., Mark B. Dekutoski, M.D., Robert S. Pashman, M.D.*, Rob House
B.S., Jack L. Lewis, Ph. D., Kirkham B. Wood, M.D., James W. Ogilvie, M.D.

Department of Orthopedic Surgery and Twin Cities Scoliosis Spine Center
University of Minnesota, Minneapolis, MN 55455

*Department of Orthopedic Surgery
University of California, San Francisco, CA 94143

INTRODUCTION

In-vivo experimental models which attempts to replicate surgical interventions, physiological alterations or pathological conditions are dependent upon controls for iatrogenic distortion of biology and mechanics. In-vivo canine models of disc mechanics (Wood, 1991), facet cartilage degeneration (Kahanovitz, 1984), device related osteopenia (Gurr K.R., 1989; K.R. Smith; 1991), cervical spine instability (Buff, 1990; Crisco 1990), cervical fusion (Whitehill, 1985 and 1987) and adjacent segment biology (Cole, 1985 and 1987) have noted soft tissue scarring and adjacent segment stiffness/ankylosis over segments which have been surgically exposed but not intentionally fused. An instability model in rabbits (Stokes, 1989) also demonstrated the stabilizing effects of scar tissue formation. The in-vivo mechanical and biological effects of this scarring/ankylosis have not been described. Identification of how the presence (or installation procedure) of an instrument effects the function one is attempting to measure is imperative to mechanical studies in living animals. The purpose of this study was to elucidate the affects of posterior surgical exposure on intervertebral motion in the canine. An instrumented spatial linkage (ISL) was used to measure lumbar intervertebral motion in canines with differing amounts of surgical insult to the paraspinal musculature and periosteum.

METHODS

Six adult male canines (25-39 kg) were divided into three groups, each group had placement of the ISL mounting pins by different methods. Group I (2 animals) had open surgical placement of 4mm Steinmann pins into the vertebral body/pedicle

junction of L2 and L3. The animals were anesthetized with intravenous sodium thiamylal (surital) (15mg/kg) and succinylcholine (0.5mg/kg), and maintained with halothane inhalation anesthetic. Crystalline penicillin was given intravenously. A dorsal-lateral approach was made with dissection of the muscles down to the pedicle/body junction. Two pins were placed into vertebral body L2 (one on each side of the segment) and two pins were placed into vertebral body L3. The wounds were irrigated and closed and animals were allowed to recover.

Group II (2 animals) had percutaneous placement of 4mm Steinmann pins into the body/pedicle junctions guided by fluoroscopy. The anesthetic procedure used was the same as for group I. A jig was created to aid the insertion of the pins. The jig consists of a central 2 mm spinous process pin used to locate the vertebral body in space. Four mm vertebral body pins were then inserted using the pin guides mounted laterally on the jig. The spinous process pin was inserted into the spinous process of L2. Under fluoroscopic control, the Steinmann pins were implanted through 0.5 cm stab incisions and advanced simultaneously. The ends of the vertebral body pins were capped and left subcutaneous. The same procedure was repeated for the adjacent vertebral body, L3.

Group III (2 animals), had percutaneous placement of 2.5 mm Schanz pins into the spinous process guided by fluoroscopy. Animals were anesthetized as in the other procedures and small skin incisions were made over the spinous process of L2 and L3. Two Schanz pins were implanted in each spinous process and all pins were cut (leaving about 1cm protruding from the bone) and capped. The skin

was closed over the capped pins, antibiotics and analgesics were given.

The motion testing procedure for all animals was the same. One week after pin implantation animals were anesthetized, pins were exposed, and the ISL was attached by using pin extenders and mounting platforms. Animals from groups I and II had 10-15cc of 0.5% Bupivacaine injected subcutaneously and intramuscularly about the pins and animals from group III had 5-7cc injected only into the subcutaneous tissues. Animals were allowed to recover from the anesthesia until their gait was steady. The ISL was attached to the recording equipment and as the animals walked voluntarily, voltage data from the ISL was collected at 20 samples per second over 5 second intervals using an A/D converter (Metrabyte Das16) and custom software (written in Asyst). The animals were anesthetized for removal of the ISL and wound closure. The ISL was calibrated with a calibration stand designed to allow calibration over the range in which motion occurred during testing. This testing sequence was repeated two weeks after the first test. When the animals were euthanized the spine motion segments were evaluated for gross evidence of tissue scarring and the vertebral bodies and ISL landmarks were digitized to obtain the constant bone to ISL transformation matrices. The experimental voltage data was used with the calibration constants and the constant transformation matrices to determine the 6 degree-of-freedom motion across the motion segment (Wood (1991)). Total facet excursion in the plane of the facet was determined from the body motion and local coordinates of facet bony landmarks determined from digitizing the ex-vivo specimens. Measurement errors using the ISL on intervertebral joints was previously determined to be ± 0.7 mm (Wood, 1991). For each group of animals the segment motion at one week and three weeks was compared via paired Student's t-test to examine if motion had changed. Group III animals were also tested five weeks after pin implantation.

RESULTS

All pins were placed without nerve root injury, canal compromise or other complications. For the animals in group I extensive scarring was noted throughout the paraspinalis muscles and facet capsules. At three weeks after implantation ex-vivo examination noted extensive scar tissue which bridged between the two implanted pins, and covered the posterior elements. At three weeks after implantation ex-vivo examination of specimens from group II animals, less scarring was noted and no bridging scar was present between pins. Group III animals had no evidence of fibrosis.

Facet excursion decreased significantly ($p < 0.001$) between one and three weeks after pin implantation for animals of group I (from 3.4 ± 0.2 mm initially to 1.1 ± 0.3 mm at three weeks) and

group II (from 3.8 ± 0.2 mm, initially to 2.0 ± 1.3 mm at three weeks), while the facet excursion of animals in group III showed no change (3.0 ± 0.2 mm initially and 3.1 ± 0.3 mm at three weeks) (figure 1). Group III canines had no diminished motion at five weeks.

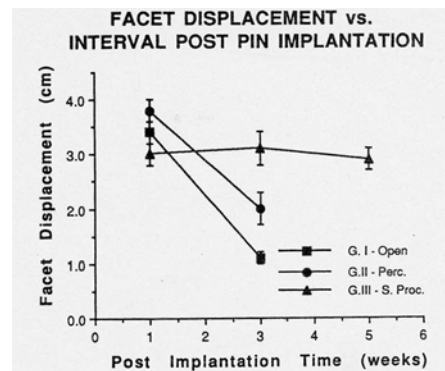


Figure 1
(Facet displacements for three groups of animals over 0 to 5 weeks. Groups with surgical exposure or violation of the posterior musculature show motion decreases, while the group with no violation of the posterior musculature show no change in intervertebral motion.)

DISCUSSION/CONCLUSIONS

ISL motion measurement by the open and percutaneous vertebral body/pedicle pin placement methods results in a significant decrease in segmental motion between one and three weeks. The cause for this likely involves changes in muscle coordination due to pain or local muscle denervation, myonecrosis from local anesthetic injection or post-operative scarring with resultant fibrous ankylosis. Use of the in-vivo canine spine model requires use of sham controls in which the full surgical exposure is controlled. Changes in motion segment mechanics affected by post-operative scarring and subsequent ankylosis can alter cartilage, bone and disc physiology. Use of spinous process pinning and the ISL motion measurement techniques does not produce this surgical artifact. This method of measuring intervertebral motion can now be used confidently in studies where motion segments are mechanically or biologically altered.

ACKNOWLEDGEMENTS

This research was supported by the Department of Orthopedic Surgery at the University of Minnesota, SCOR grant AR39255, and OREF Bristol Meyers/Zimmer Institutional grant.

REFERENCES

1. Buff HU, Panjabi, MM Sonu CM, Crisco JJ, Oxland TR, Pelker RR. Functional Stability of the Canine Cervical Spine After Injury. **Spine** **15**: 1040-1046, 1990.
2. Cole T, Burkhardt D., Ghosh P, Hannan NJ, Taylor KF, Bellenger CR: The Response to the Canine Intervertebral Disc to Immobilization Produced by Spinal Arthrodesis is Dependent on Constitutional Factors. **Journal of Ortho. Res.** **5**: 337-347, 1987.
3. Cole T, Burkhardt D., Ghosh P, Ryan M, Taylor T: Effects of Spinal Fusion on the Proteoglycans of the Canine Intervertebral Disc. **Journal of Ortho. Res.** **3**:277-291, 1985.
4. Crisco JJ, Panjabi MM, Wang E, Price MA, Pelker RR. The Injured Canine Cervical Spine after Six Months of Healing. **Spine** **15**: 1047-1052, 1990.
5. Gurr KR, McAfee PC, Warden KE, Shih CM. Roentgenographic and Biomechanical Analysis of Lumbar Fusions: A Canine Model. **Journal of Ortho Res.** **7**: 838-848, 1989.
6. Kahanovitz N, Arnoczky SP, Levine DB, Otis JP: The Effects of Internal Fixation on the Articular Cartilage of Unfused Canine Facet Joint Cartilage. **Spine** **9**: 268-272, 1984.
7. Smith KR, Hunt TR, Asher MA, Anderson HC, Carson WL, Robinson RG: The Effect of a Stiff Spinal Implant on the Bone Mineral Content of the Lumbar Spine in Dogs. **J. Bone and Joint Surg.** **73 (A)**: 115-123, 1991.
8. Stokes IAF, Counts DF, Frymoyer JW: Experimental Instability in the Rabbit Lumbar Spine. **Spine** **14**: 68-72, 1989.
9. Whitehill R, Barry JC. The Evolution of Stability in Cervical Spine Constructs using Either Autogenous Bone Graft or Methylmethacrylate Cement: A Follow-up Report on a Canine In-vivo Model. **Spine** **10**: 32-41, 1985.
10. Whitehill R, Stower SF, Fechner RE, Ruch WW, Drucker S, Gibson LR, Mckernan DJ, Widmeyer JH. Posterior Cervical Fusions Using Cerclage Wires, Methylmethacrylate Cement and Autogenous Bone Graft: An Experimental Study of Canine Model. **Spine** **12**: 12-22, 1987.
11. Wood KB, Schendel MJ, Buttermann GB, Lewis JL, Olgilvie JW: In-Vivo Analysis of Canine Intervertebral and Facet Motion. Transactions of the 37th Annual Meeting of the Orthopedic Research Society, p. 46, 1991.