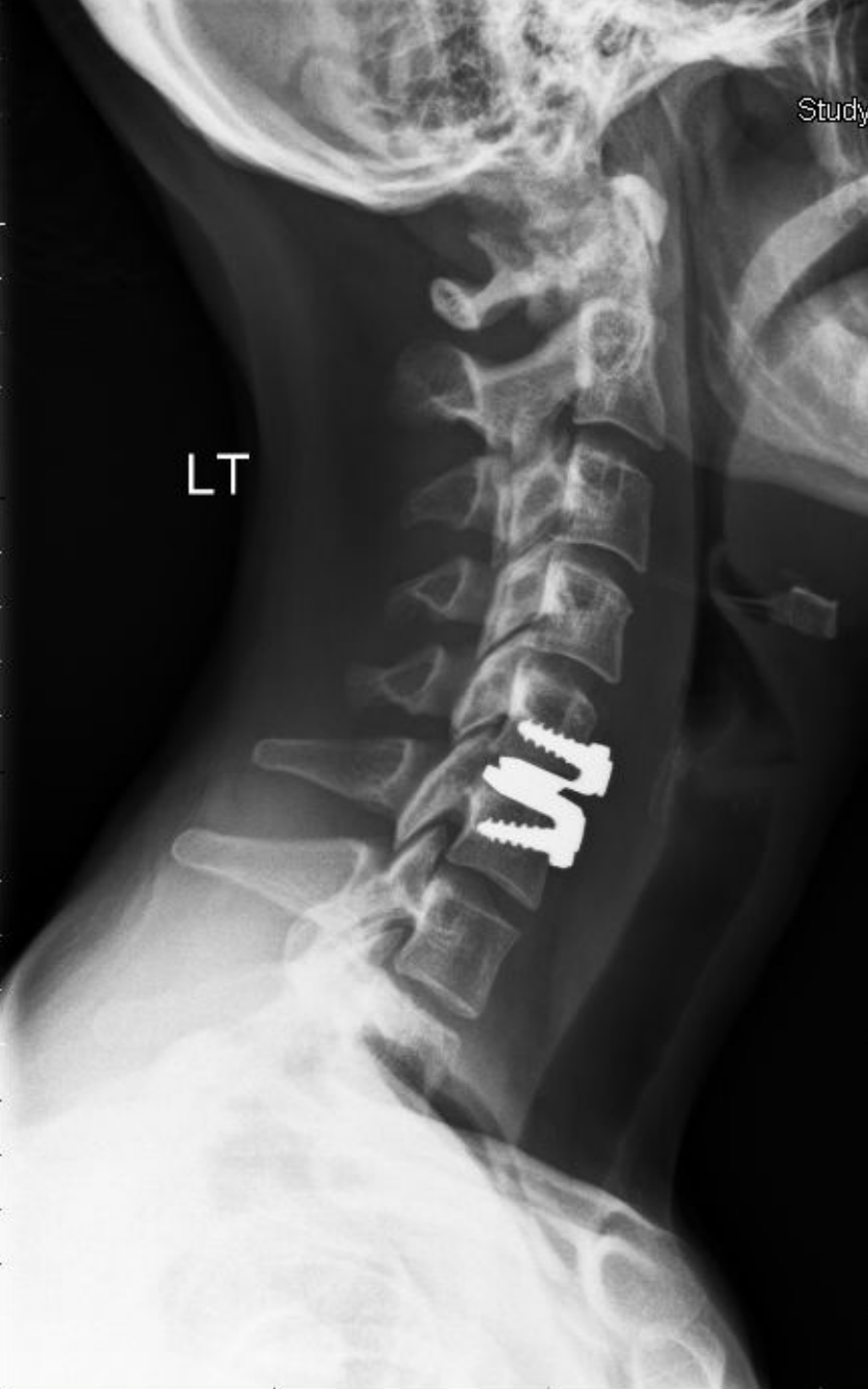



Case Review:

A Massive C5/6 disc herniation treated urgently with a Prestige Artificial Disc

Robert S Pashman, MD

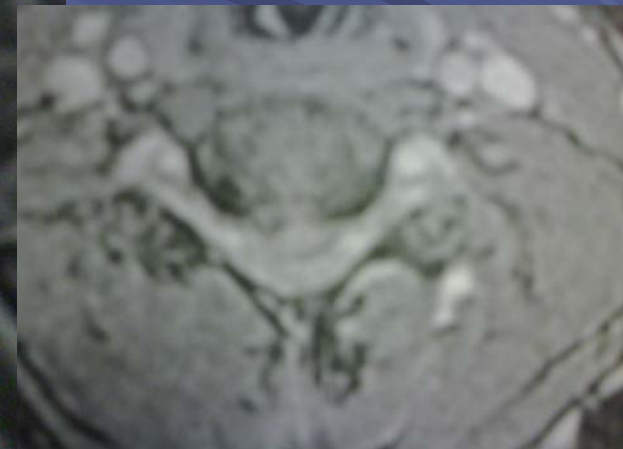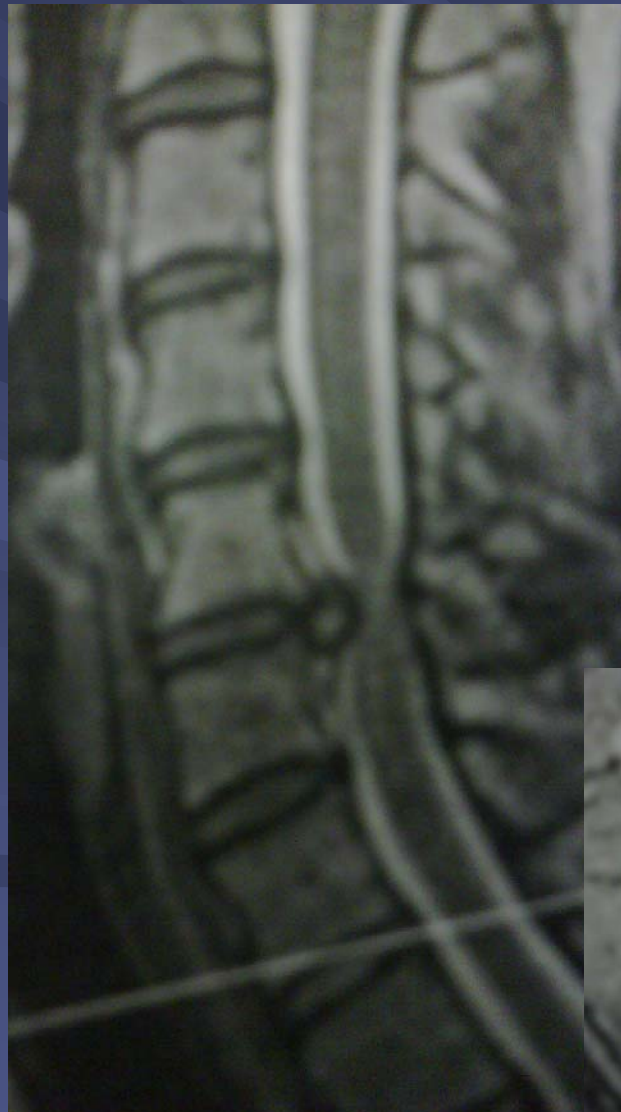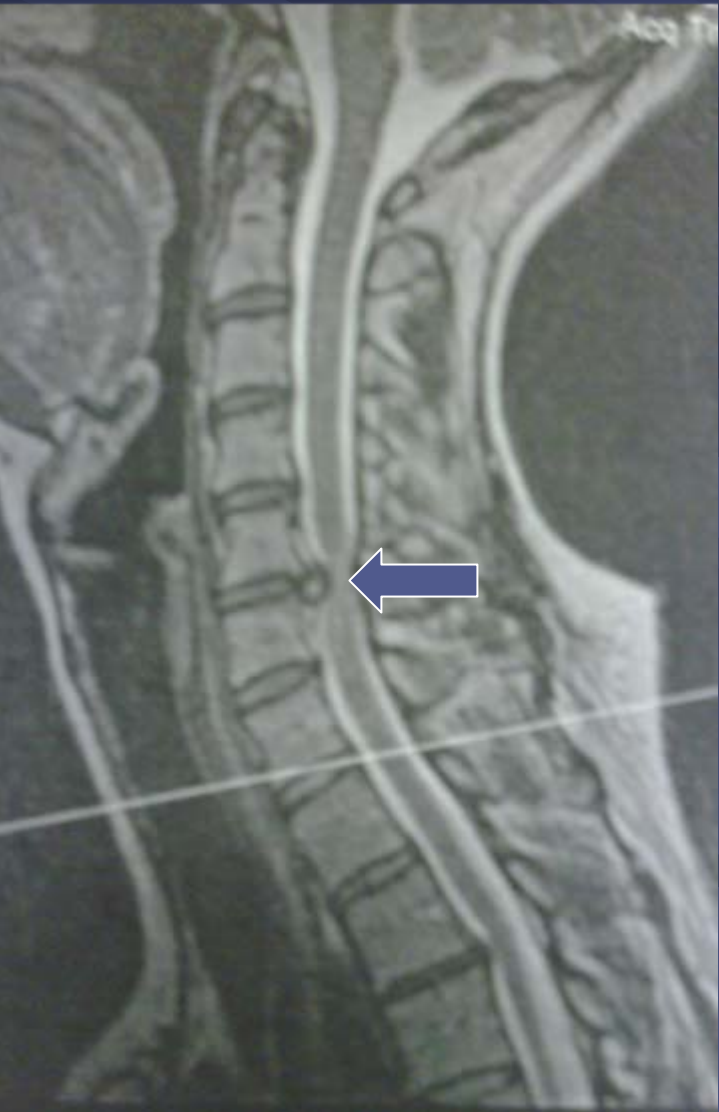Scoliosis and Spinal Deformity Surgery

www.NeckPainExplained.com

Patient History

- 36 year old female
- Patient presented with neck pain radiating to the bilateral trapezial region, numbness and weakness in the hands, for approximately 3 weeks.
- She has had PT, yoga and chiropractic, but no nerve blocks or medicines.
- She went to see physiatry who ultimately referred her over to a spine surgeon who discussed alternatives of various surgeries, but then discharged her without medicine or protection. She sought another surgical opinion, but the physician had not performed Total Disc Replacement surgery on a patient before. The same day she had a consult in my office. The patient then came to see me for complaints of trapezial pain, numbness and weakness in the hands. At this point, the patient says that she has clumsiness in her hands and weakness. The patient had difficulty with forced abduction of her arms over her head at this point.
- On MRI the patient has a massive extruded disk herniation at C5-6 causing myeloradiculopathy with impending severe neurologic deficit including numbness and tingling in the hands, weakness, trapezial upper extremity with hyperreflexia in the upper and lower extremities and upper motor neuron signs.

Pre-op Films



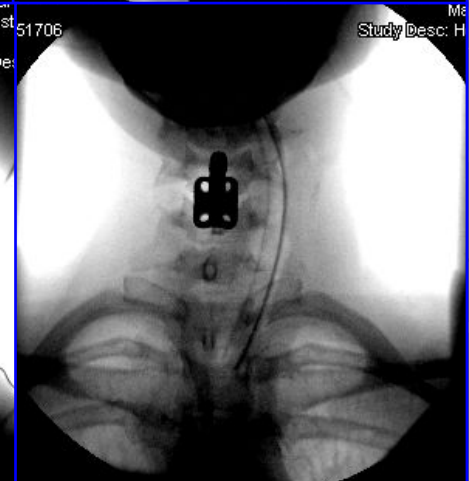
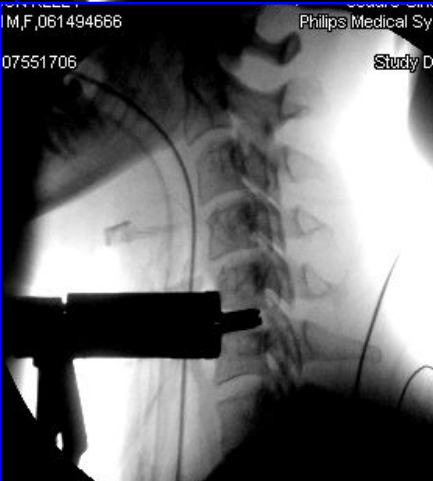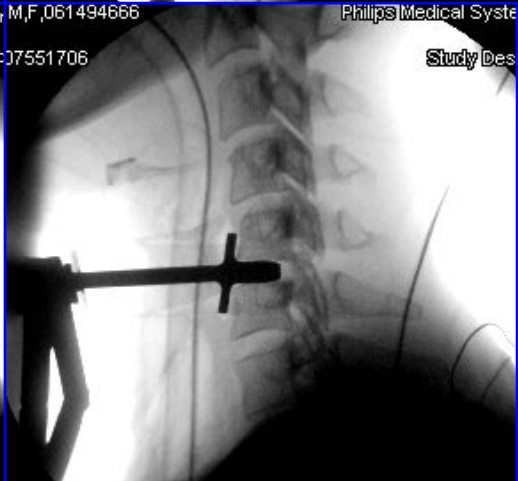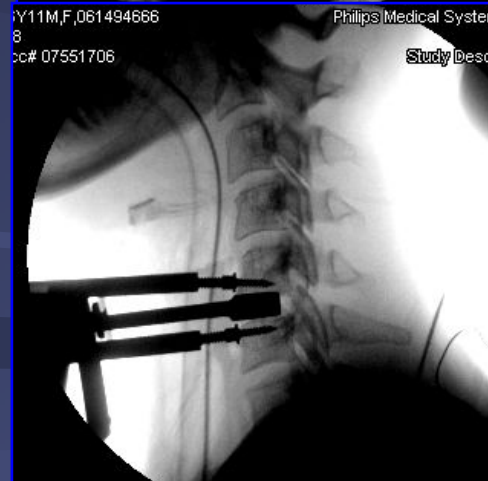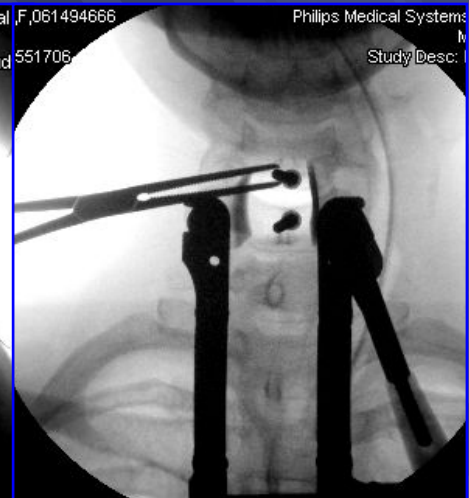
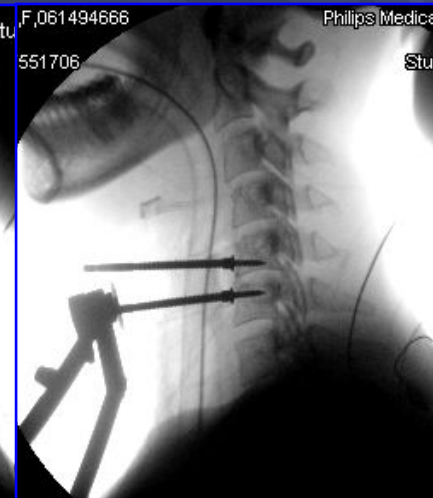
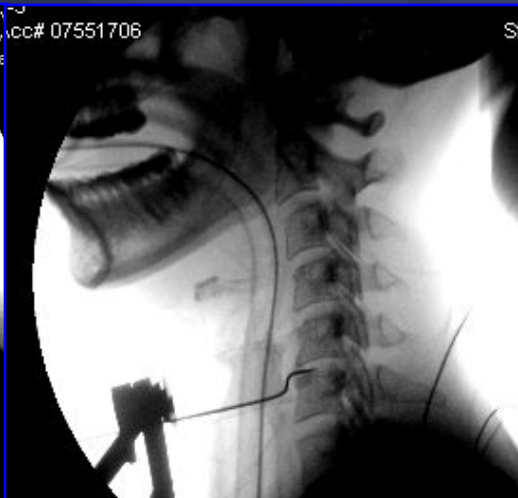
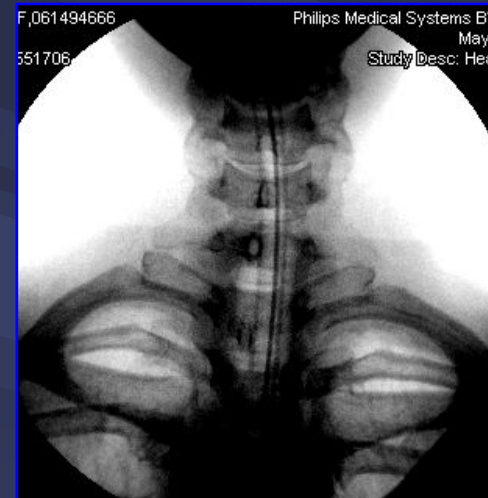
Indications for Surgery

1. Massive extruded disk herniation, C5-6, with myeloradiculopathy.
2. Spinal cord compression with evolving upper motor neuron signs, weakness in the upper and lower extremities, evidence of severe nerve compression.
3. Degenerative disk disease, C5-6.
4. Failed conservative therapy.
5. Evidence of normal disks proximal and distal to extruded disk herniation, C5-6.

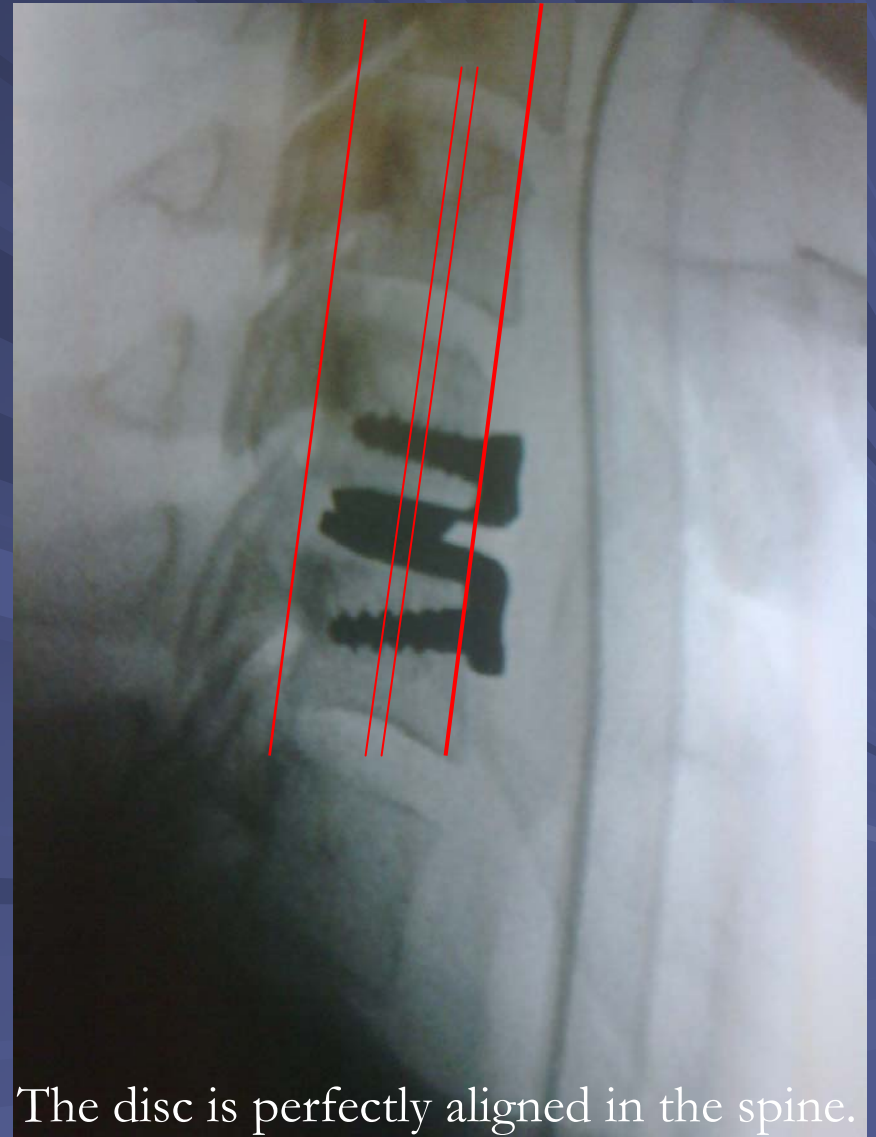
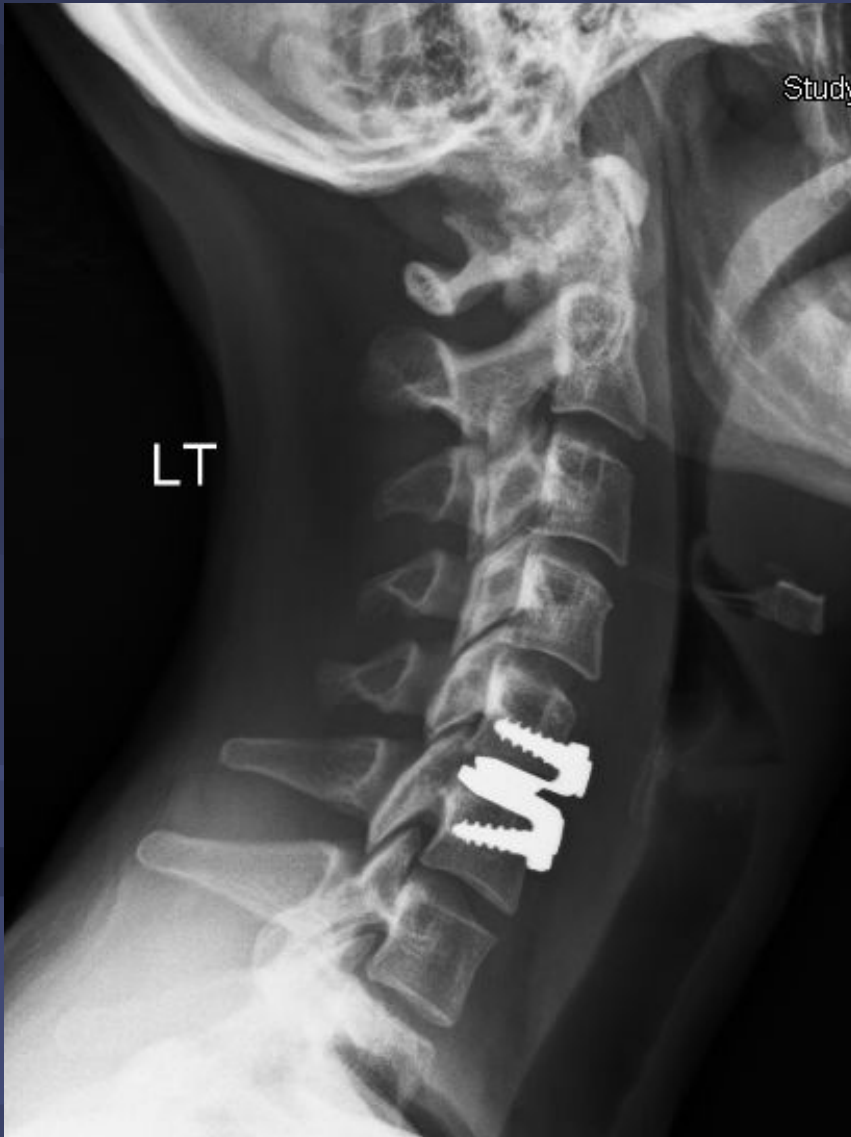Surgical Strategy

- Radical diskectomy, spinal cord decompression under the microscope, C5-6.
- Placement of Prestige Artificial Disc replacement measuring 6x16, at C5-6.
- Intraoperative somatosensory evoked potentials.
- Intraoperative fluoroscopic control.

Intraoperative Films



Post-operative Films



The disc is perfectly aligned in the spine.