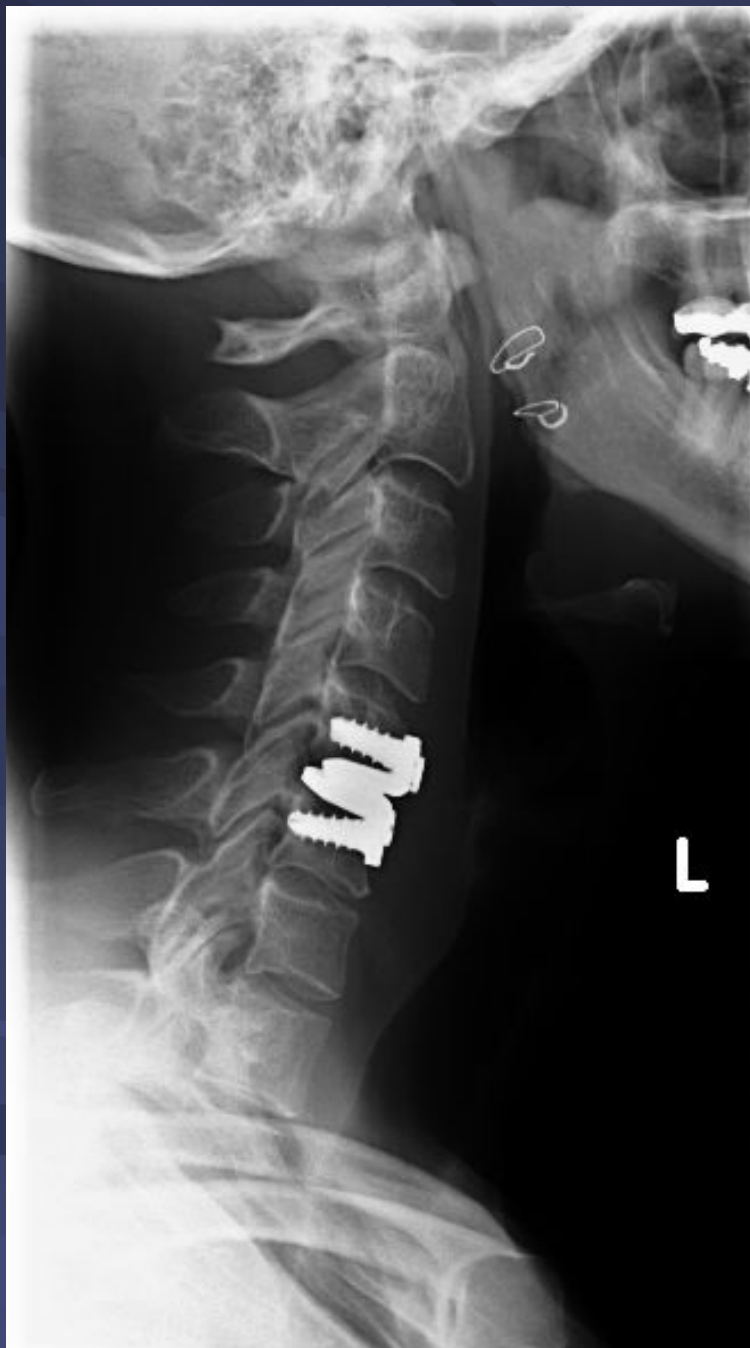



Case Review:

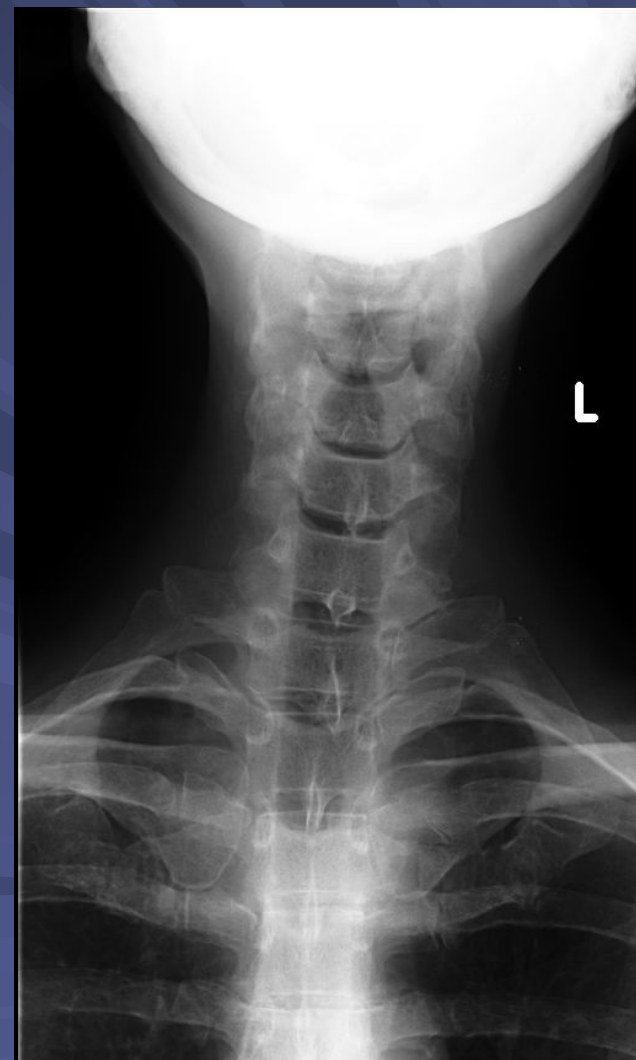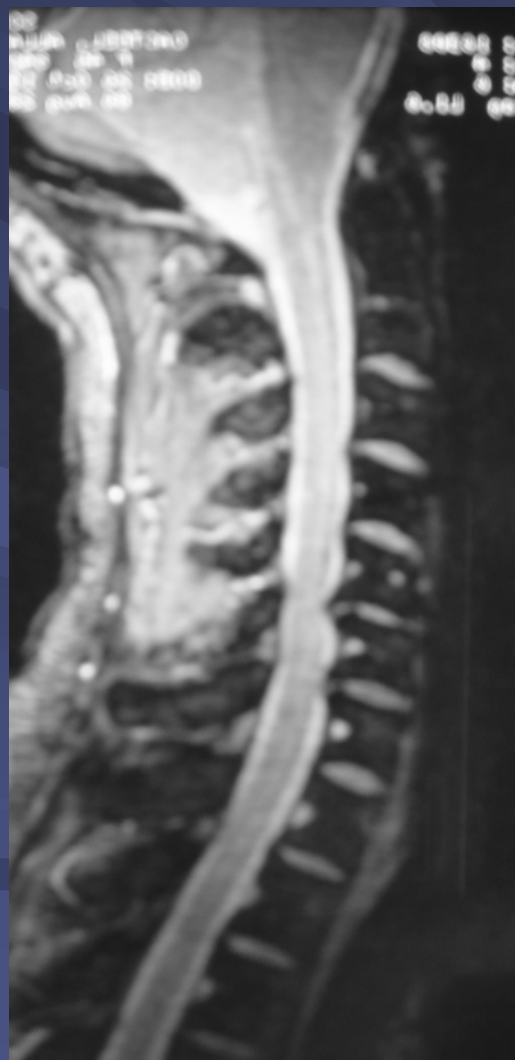
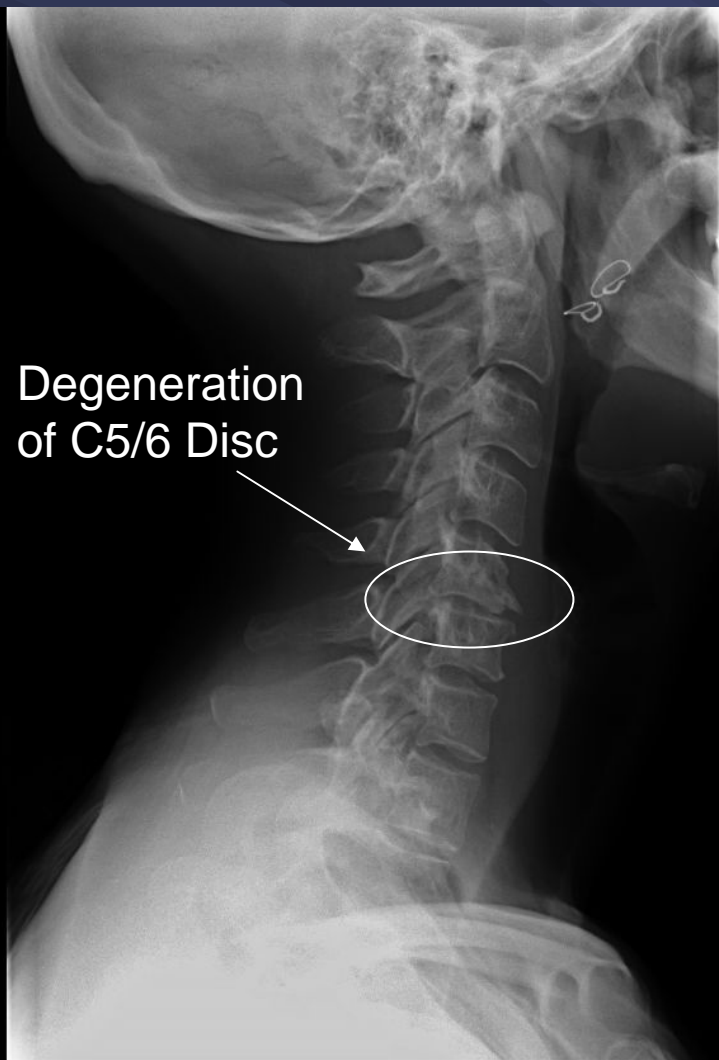
Herniated C5/6 treated with
a Prestige Artificial Disc

Robert S Pashman, MD
Scoliosis and Spinal Deformity Surgery
www.NeckPainExplained.com

Patient History

- 46 year old female
- Massive neck pain
- Arm pain
- Failed conservative therapy
- Escalating intake of pain medication
- Degeneration of C5/6, osteophytes, spinal cord compression and stenosis found on MRI

Pre-op X-rays



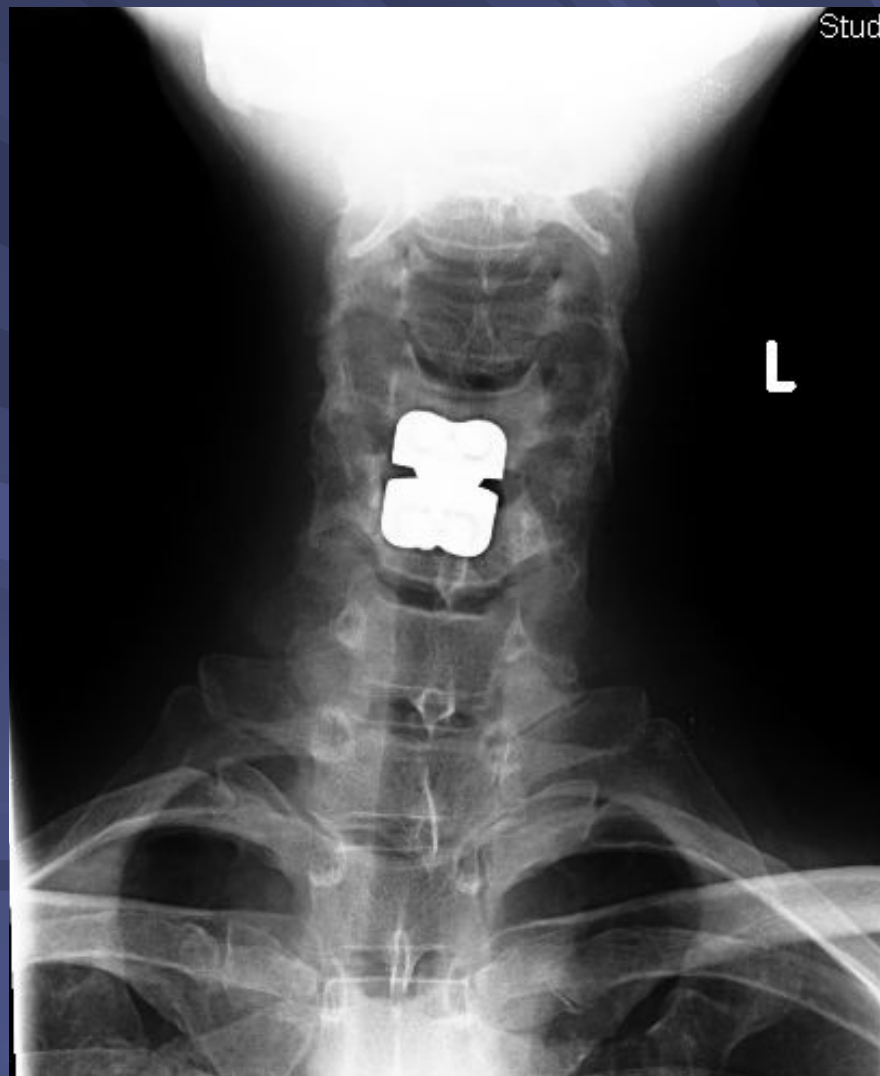
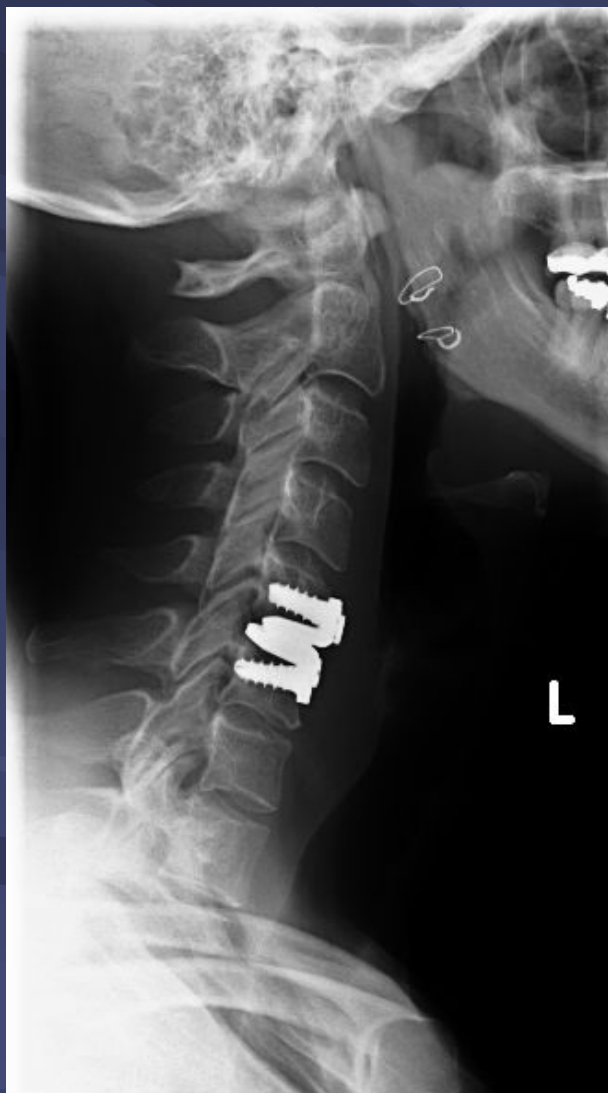Indications for Surgery

- Degenerative disc disease of C5-6.
- Neuroforaminal stenosis of C5-6.
- Degenerative disc disease of the spinal cord and neuroforaminal C6 compression.
- Severe uncovertebral osteophyte causing spinal cord and neuroforaminal compression necessitating vertebrectomy.
- Failed conservative therapy.

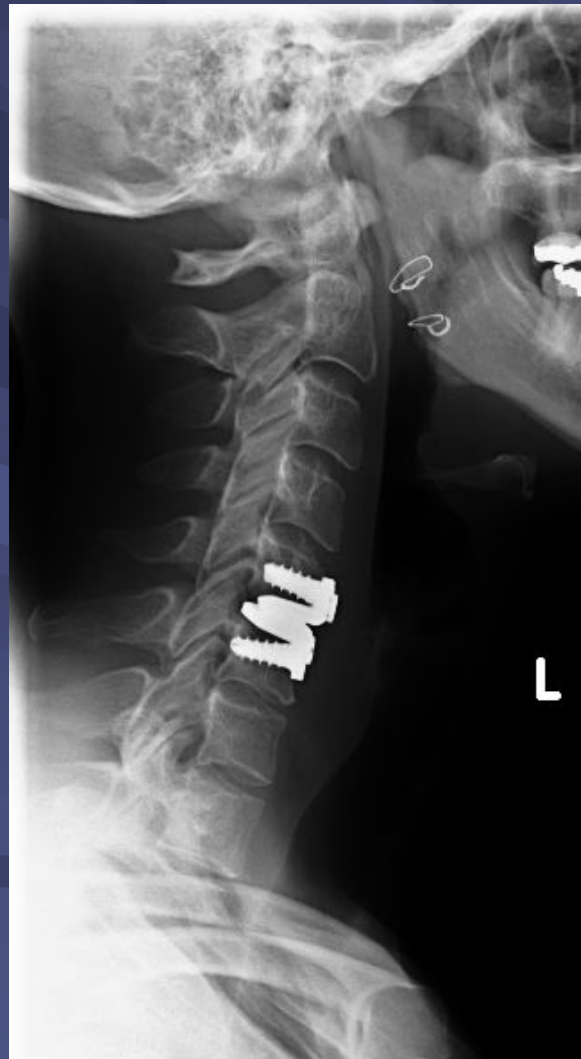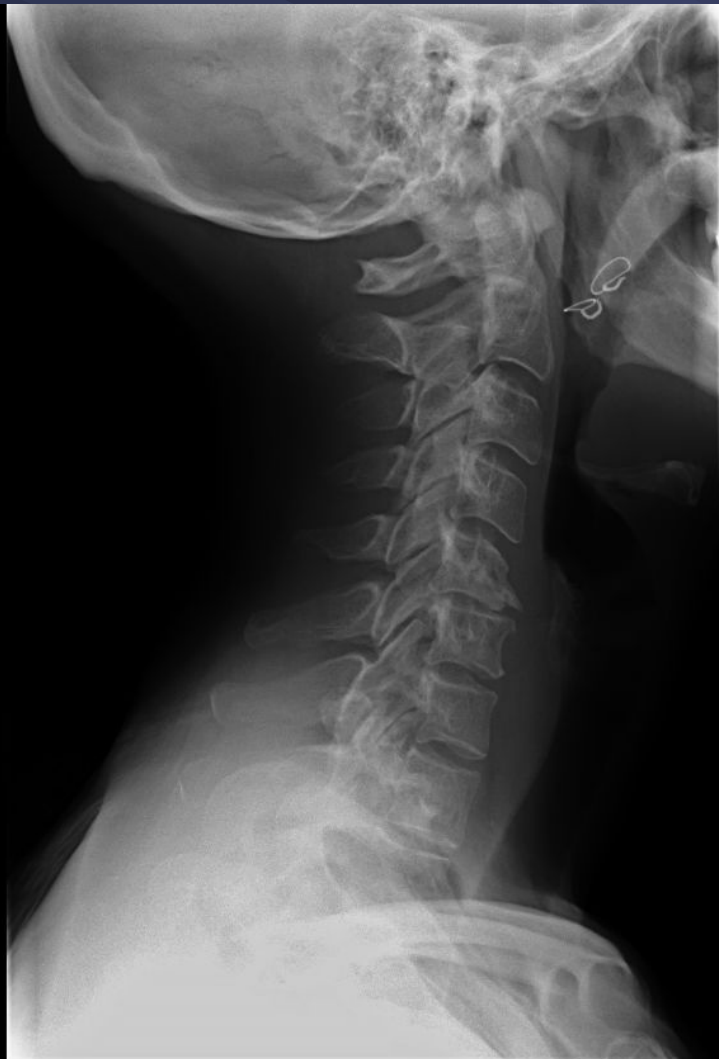Surgical Strategy

- Radical discectomy with complete spinal canal evacuation of soft disc.
- Subtotal vertebrectomy C5-6 for removal of mass of uncovertebral osteophyte and neuroforaminal stenosis.
- Cervical total disc replacement using Prestige 6 x 14 implant.
- Intraoperative SSEP.
- Intraoperative fluoroscopy.

Post-Op Films



Pre-Op/Post-op Comparison



The patient is doing well postoperatively. Her neck and arm pain were resolved.